

# Superficial enhanced fluid fat injection (SEFFI and MicroSEFFI) in facial rejuvenation

A. Gennai<sup>1</sup>, F.P. Bernardin<sup>2</sup>

<sup>1</sup>Plastic, Reconstructive, and Aesthetic Surgery, University of Camerino, Camerino, Italy

<sup>2</sup>Private Oculoplastic Surgery, Genova, Italy

Corresponding Author: Alessandro Gennai, MD; e-mail: agennai@mac.com

**Keywords:** SEFFI, MicroSEFFI, Facial rejuvenation, Lipofilling, ADSC, Stem cell.

## ABSTRACT

**The skin aging and the loss of volume are the most involved processes in facial aging; the injection treatment with viable adipocytes and Adipose-Derived Stromal and stem Cells (ADSC) promises to restore the volume and regenerate the skin. To achieve a higher adipocytes engrafting rate and a skin regenerative effect by ADSC the small tissue clusters must be injected superficially into the dermal and subdermal layers. The Authors describe SEFFI and MicroSEFFI techniques which through an innovative harvesting procedure provide three different kinds of injectable tissue with tissue clusters of different size: these three different tissues are injected in the dermal and subdermal layers of the different face areas that have different skin and subdermal thickness thus minimizing the risks of visibility and lumpiness.**

## INTRODUCTION

There has been a significant increase in the number of requests for facial rejuvenation procedures from individuals aging 45 to 55 years. In this age range, the aging process is mainly ascribable to loss of volume and skin aging, possibly associated with the descent of tissues at variable degrees<sup>1</sup>.

The techniques of choice for facial rejuvenation in individuals with this age range are aimed at restoring the volume lost and at regenerating the skin.

In 1997, Coleman standardized a procedure that uses the autologous fat tissue to restore volumes of the face<sup>2-5</sup>. Autologous adipose tissue was described as the ideal filler, delivering natural filling

in a safe and easy procedure. In this procedure, adipose tissue is used in autologous and homologous settings: along with immunologic compatibility, the effects are durable, and there is a low risk of infections<sup>6</sup>. Since the very first introduction of this procedure, the relatively fast rate of absorption of the adipose filling has been one of the main issues. This problem has been resolved thanks to more sophisticated techniques improving the effectiveness and reliability of the treatment.

In 2001, Zuk et al<sup>7-9</sup> described the human adipose tissue as a source of multipotent mesenchymal stromal/stem cells (MSC) similar to those found in the bone marrow. Today, these adipose stem cells (ASCs) are among the most investigated and used cells in the field of regenerative medicine. ASCs are found in the stromal vascular fraction (SVF) of the adipose tissue<sup>10</sup>. The SVF contains large numbers of cells composing interrelated cell populations: ASC progenitors, pericytes, endothelial progenitor cells, and transit amplifying cells<sup>11</sup>. In the last 15 years, a large body of work conducted on ASCs reported their capacity to differentiate into multiple cell types, including adipocytes, chondrocytes, myocytes, hepatocytes, endothelial cells – both *in vitro* and *in vivo*<sup>12,13</sup>. Also, ASCs display the ability to secrete bioactive molecules which stimulate angiogenesis and have antifibrotic, antiapoptotic and immunomodulatory properties<sup>14,15</sup>. Moreover, SVF/ASCs induce the secretion of cytokine and growth factors which promote angiogenesis and thus revascularization of fat grafts<sup>16,17</sup>. Such characteristics of SVF/ASCs could account for some effects observed after adipose tissue implantation, such as improved skin trophism, accelerated closure of complex wounds or ulcers, and enhancement of skin appearance after damage from radiotherapy<sup>4,18-20</sup>.

The transplantation of viable adipocytes and SVF/ASCs-enriched fat grafts, therefore, yields a combination of volumization and skin regeneration effects<sup>20-22</sup>. This opens the way for what can be called regenerative therapy in the field of plastic surgery.

Many studies have demonstrated that an increased adipocyte engraftment and a more effective regenerative action can be obtained by injecting fat tissue and SVF/ASCs superficially (subdermal plane injection), and the smaller the adipose clusters injected, the better the results obtained<sup>23,24</sup>.

James et al<sup>6</sup> focus on the evidence proving that ASCs are critical to adipocytes engraftment, and maintain that the regenerative action is often more relevant than the volumizing one to achieve the effect of rejuvenation.

Moreover, when small (0.2 to 0.8 mm) adipose tissue clusters are injected, the cellular blood irrigation is improved – along with the degree of engraftment.

The group emphasized that when placing fat, it is imperative to maximize the surface area contact with surrounding tissue to ensure proximity of grafted fat with the vasculature of the recipient. Larger globules of fat undergo central necrosis, volume loss, and may result in oil cysts<sup>6,25</sup>.

In the light of such evidence it is now clear that obtaining an effective and long lasting volumizing and regenerating facial effect through graft of fat and SVF/ASCs requires tissue with the following characteristics:

1. Containing viable adipocytes (volumizing action)
2. Containing SVF/ASCs (regenerating action)
3. Consisting of small adipose clusters below 1 mm in size (0.3-0.8 mm) so that cellular blood irrigation is improved and injection can be made superficially (subdermal plane) with a needle (21-27G) or a thin microcannula (0.8-0.4 mm) with no risk of skin irregularities or lumpiness.

The surgical technique should have the following characteristics:

- a. Superficial injection (subdermal)
- b. Injection of adipose clusters in a linear way, so as to avoid tissue clogs which might compromise irrigation of the core part resulting in a cellular necrosis.

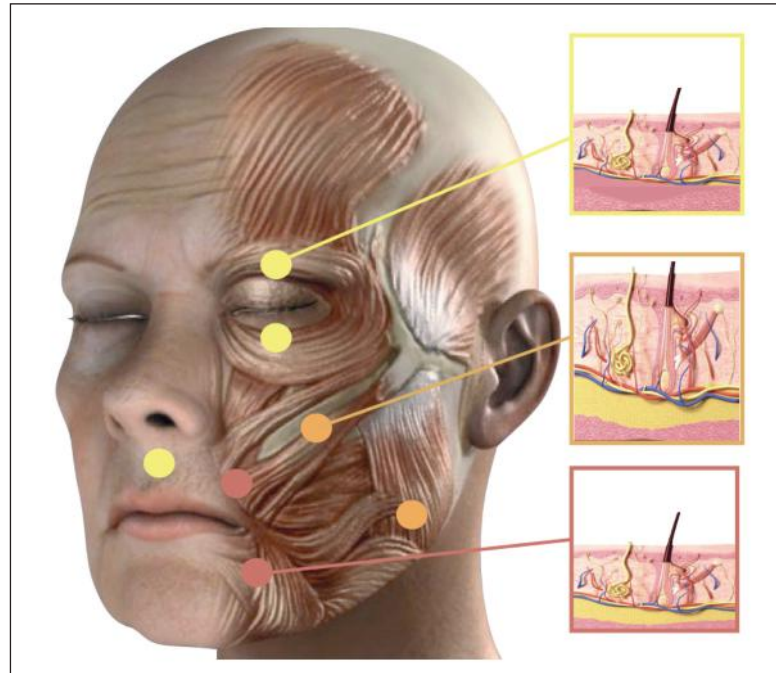
Treatments aimed at facial rejuvenation require knowledge of the characteristics of this anatomical region. The face is a very peculiar anatomical district where areas possess varying cutaneous and subcutaneous thickness. Different areas may, therefore, respond differently to the subdermal implantation of adipose tissue and SVF/ASCs. The skin in the periocular area at the level of the *eyelid sulcus* and *orbit frame* is extremely thin and adheres to the *orbicularis oculi muscle* without any proper subcutaneous layer. Similarly, the skin in the *perioral* area is also very thin and has no subcutaneous tissue; in the *zygomatic malar* region the skin thickness varies considerably depending on gender, age and genetic characteristics of the patient, and the same applies to the *malar* region. No subcutaneous adipose tissue underlies the temporal region which adheres to the temporal fascia. The big variability in thickness and quality of the cutaneous and subcutaneous tissue make it extremely difficult to use a single type of tissue preparation for injection, especially when considering the problems related to the superficiality of implantation, such as skin irregularities, and lumpiness (Figure 1).

Many techniques have been proposed to meet such characteristics in the last few years. Manipulation techniques have been developed to obtain an injectable tissue, fluid enough to be injected superficially with needles (21-27G) or thin cannulas (0.8-0.4 mm).

### SEFFI AND MICROSEFFI

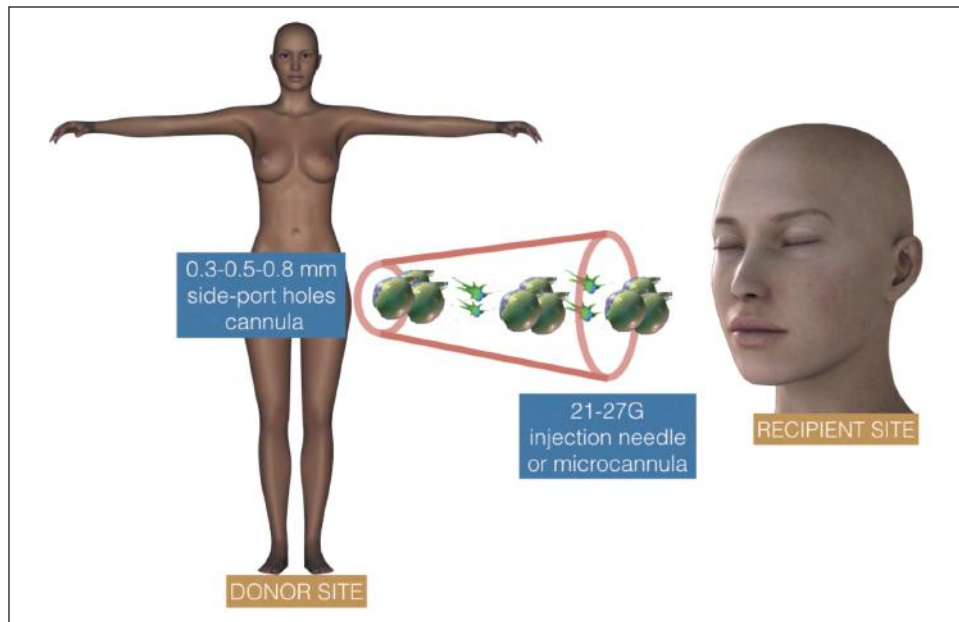
Superficial Enhanced Fluid Fat Injection (SEFFI)<sup>26,27</sup> and its evolution MicroSEFFI<sup>28</sup> are grafting techniques for adipose tissue designed to deliver viable adipocytes and SVF/ASCs for the 1) restoration of face volumes, 2) enhancement of skin appearance and, 3) reduction of superficial facial wrinkles. SEFFI and MicroSEFFI can be performed as a single procedure or in combination with other rejuvenation procedures for the face and the eye, such as Minimal Incisions Vertical Endoscopic Lifting (MIVEL)<sup>29-31</sup>, blepharoplasty and neck lift. The combination of the SEFFI and MicroSEFFI technique with the MIVEL endoscopic lifting of tissues enables the correction of three main causes of face aging: volume loss is restored, tissue regeneration is promoted, descended tissues are repositioned. This technique has been standardized by its authors and called R3 (R cubed)<sup>1</sup>.

**Figure 1.** The thickness of the subcutaneous adipose tissue changes in the different areas of the face: it is almost absent in the periocular area and the perioral area.

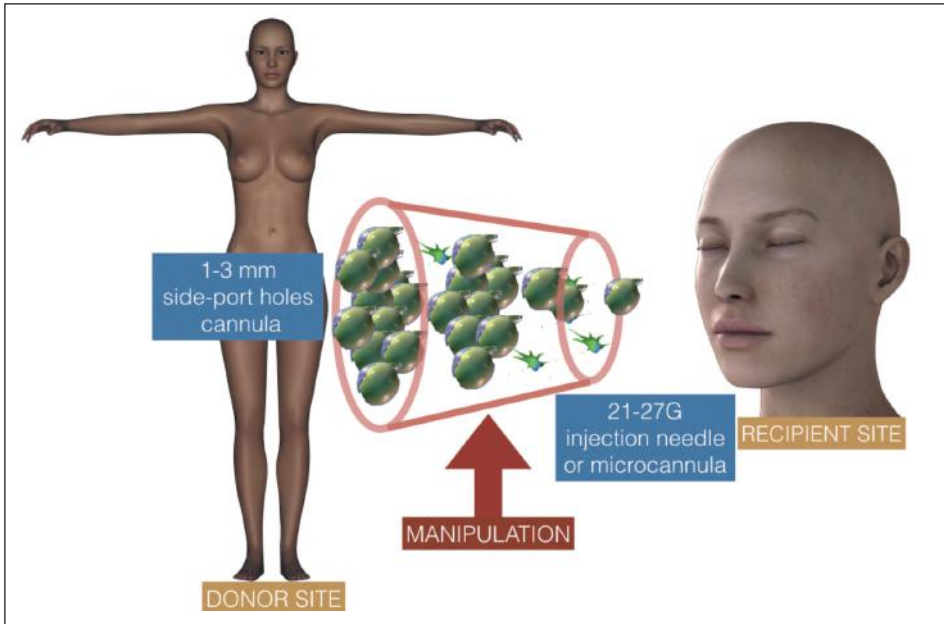


The SEFFI and MicroSEFFI techniques are based on the rationale that a highly fluid preparation of adipose tissue clusters can be generated in the harvesting step. In SEFFI and MicroSEFFI, adipose tissue is dissociated in small clusters by harvesting with a cannula with small side-port holes, the tissue preparation is then enriched with PRP (Platelet Rich Plasma), and subsequently injected via needles or cannulae of larger diameter (Figures 2, 3).

The SEFFI and MicroSEFFI techniques use harvesting cannulas that are especially designed and manufactured: SEFFI cannulas are equipped with 0.8 or 0.5 mm side port holes, MicroSEFFI cannulas are equipped with 0.3 mm side port holes. The three cannulas have Louer Lock connectors (for use with 10ml syringes). They are 15 cm in length, 2 mm in diameter and are provided at their tip with 15 side port holes of 0.8 mm, 0.5 mm and 0.3 mm respectively. In the holes of the



**Figure 2.** In SEFFI and Micro SEFFI, the side portholes of the harvesting cannulas are smaller than the holes of the injecting cannulas or needles.



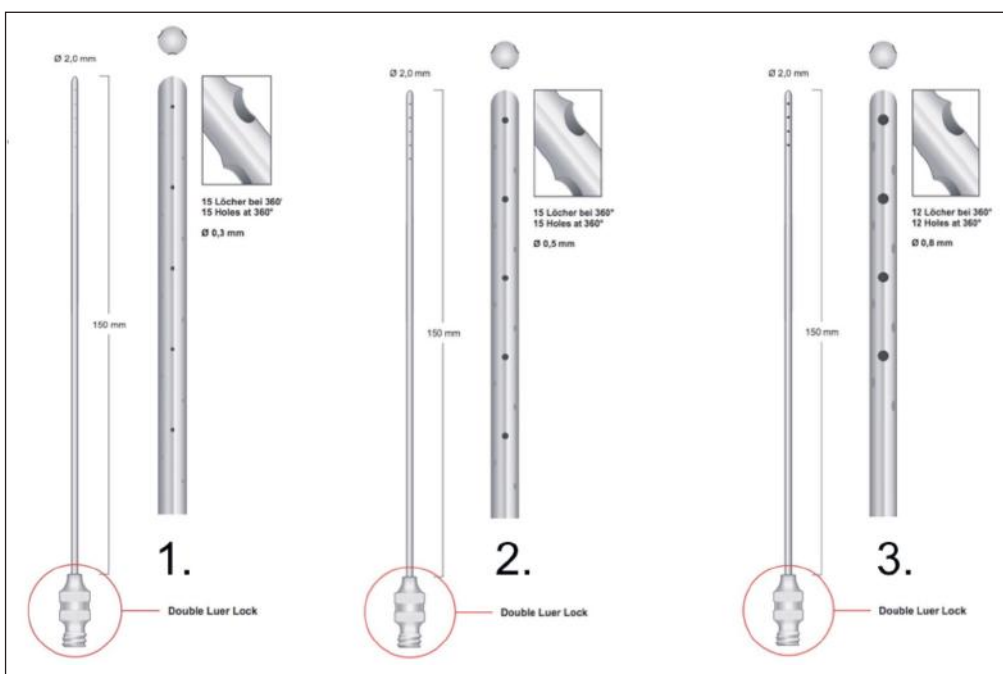
**Figure 3.** Microfat and Nanofat published techniques: the side port holes of the harvesting cannulas are larger than the holes of the injecting cannulas or needles. Hence, further manipulation of the tissue clusters is required to increase fluidity and enable injection.

larger SEFFI cannulas (0.8 and 0.5 mm) small teeth facilitate the inflow of tissue (these cannulae are manufactured by Bmed Surgical Instruments Italy) (Figure 4).

#### SEFFI AND MICROSEFFI PROCEDURE

Fat aspiration is performed while the patient is maintained under local anesthesia and monitored intravenous sedation. The following protocol has

been standardized. Cold Ringer's lactate solution (500 mL) was mixed with lidocaine (500 mg), sodium bicarbonate (5 mEq) and epinephrine (1 mg), then injected into the selected donor site: this 1:500,000 anesthetic solution is injected into the selected donor site with a ratio 1:1 of the average amount of harvesting tissue. Manual aspiration of the adipose tissue was performed with a 10 mL syringe mounted alternatively with the three



**Figure 4.** SEFFI and MicroSEFFI harvesting cannulas manufactured by Bmed Surgical Instruments, Italy.

different multi-perforated side-port cannulas. The following fat depots were chosen as preferred harvesting sites: suprapubic region, hip, pertrochanteric region, and inner aspect of the knee. Neither the type of surgical procedure nor the anatomical site of the subcutaneous adipose tissue harvesting affects significantly the total number of viable cells that can be obtained from the SVF<sup>32</sup>.

After the aspiration syringe had been filled, the fat was mixed with cold Ringer's solution to rinse the anesthetic from the fat and to facilitate tissue precipitation<sup>33</sup>. The syringe was then capped and maintained in a dark environment, under a sterile cloth, to reduce the possibility of light oxidation of adipocytes. The tissue harvested with 0.3, 0.5 and 0.8 mm side port cannulas were kept in separate, labeled syringes. The tissue was centrifuged for 1 minute at 2000 rpm, with an estimated gravitational force of 448 g. The liquid part, collected at the bottom of the syringe, was then eliminated as well as the free oil on top of the tissue. Autologous Platelet Rich Plasma (PRP) was added to the tissue (20% of the tissue)<sup>34</sup>. We observed that addition of PRP (20%) to the tissue preparation increases the cell growth in both the tissue samples harvested with the SEFFI (0.5 mm) and the Micro-SEFFI (0.3 mm) harvesting procedures<sup>29</sup> (Figure 5).

Moreover, recent studies<sup>35,36</sup> showed that the combination with PRP and SVF/ASCs increases the rate of engraftment of adipose tissue. It has been reported that PRP may increase fat graft survival by 1) providing nutrient support from its plasma components; 2) increasing angiogenesis from multiple angiogenic growth factors, such as PDGF, platelet-activating factor, and VEGF; and 3) enhancing the proliferation and adipogenic differentiation of ASCs in the regeneration zone<sup>37</sup>. Platelet-rich plasma (PRP) is a concentration of platelets in a small volume of plasma. PRP contains multiple growth factors, including: platelet-derived growth factor (PDGF), basic fibroblast growth factor (bFGF), epidermal growth factor (EGF), vascular endothelial growth factor (VEGF), insulin-like growth factor-1 (IGF-1), and transforming growth factor- $\beta$  (TGF- $\beta$ ) – released after platelet activation<sup>38</sup>. *In vitro* studies suggest that PRP enhances ASC proliferative and secretory functions<sup>39,40</sup>, whereas *in vivo* data has shown improved fat graft retention<sup>34,41,42</sup>. However, there is no consensus among experts in the field. A recent trial by Rigotti et al<sup>35</sup> reported no benefit when adding PRP to ASC-enriched fat grafts for facial rejuvenation. In this case, PRP

resulted in increased inflammation and undesirable vascular changes.

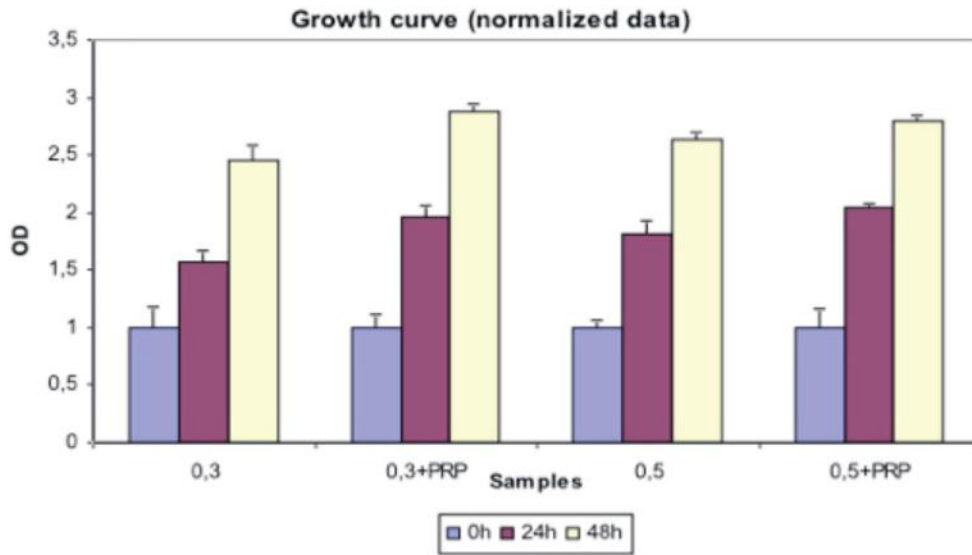
Autologous blood was drawn from the patient to prepare platelet-rich plasma (PRP). The blood was directly poured into six 4.5 mL citrate-containing Vacutainer tubes and centrifuged at 1100 g for 10 minutes; PRP was prepared in all cases with approval of the transfusion service.

The three different tissues prepared as described above (SEFFI 0.8, 0.5 and MicroSEFFI 0.3) have different degrees of fluidity and can be injected into the subdermal plane of the face with needles or microcannulas from 27G down to 21G in size (0.4-0.8 mm). It has been shown that all three tissues contain viable adipocyte, but cellularity (SVF/ASCs) decreases as the size of the hole decreases<sup>27,28</sup>. Fluidity, instead, increases as the hole size and cellularity decrease (Figure 6 A,B).

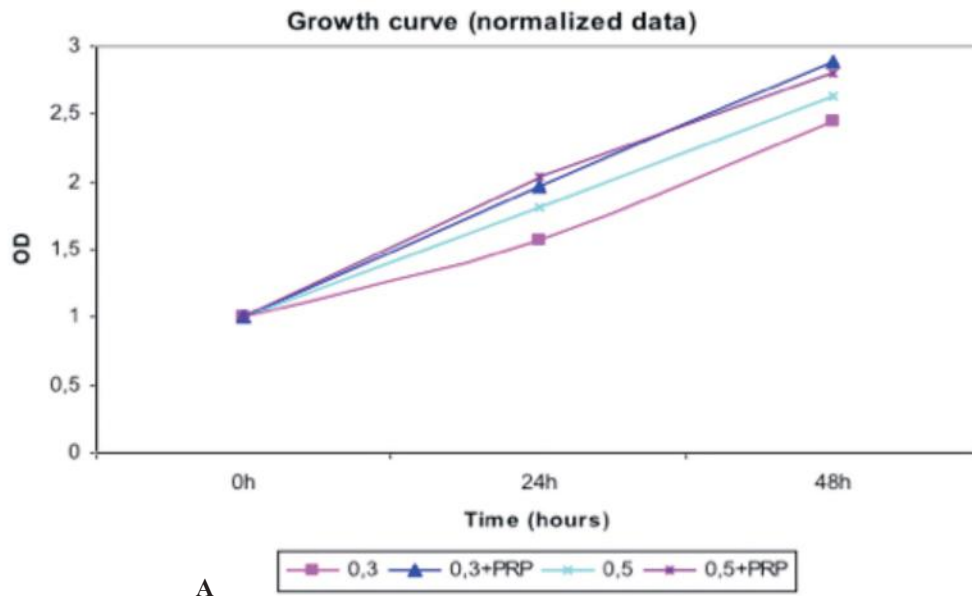
Following the preoperative plan, the three different kinds of harvested fat are injected superficially (subdermal injection) into several different anatomical regions. A needle or a microcannula was used, with decreasing diameter as fluidity increases. In those anatomical sites where the skin is thin (upper eyelid sulcus, lower eyelid sulcus, lateral canthus, upper lip), tissue harvested with 0.3 mm side portholes cannula is injected (MicroSEFFI). In anatomical sites where the skin is thicker (zygomatic malar region, mandibular arch, chin, temporal region), tissue harvested with 0.8 mm side portholes cannula is injected (0.8 SEFFI). In the sites with an intermediate skin thickness (orbital area, nasolabial sulcus, lower lip commissure and lip) tissue harvested with 0.5 mm side portholes cannula is injected (0.5 SEFFI) (Figure 7).

## CLINICAL RESULTS

A total of 263 consecutive patients were treated between January 2013 and July 2016 (cases). All patients signed an informed consent. In 126 cases (48%) SEFFI and MicroSEFFI were performed as a single procedure and in 137 cases (52%) in combination with other facial rejuvenation surgical procedures such as MIVEL, neck lift, or blepharoplasty. The average age was 47.8 years (range 34-64 years). The average implanted volume of SEFFI and MicroSEFFI was 31.2 mL (range 12-38 mL): the average implanted volume of MicroSEFFI was 3.3 mL (range 0.5-6 mL) (10.6%), SEFFI 0.5 was 8.6 mL (range 3.5-12 mL) (27.6%) and SEFFI 0.8 was 19.3 mL (range 15-24.5 mL) (61.9%). The average harvesting procedure time was 24 min 27 sec (range 6-32 minutes) (Figure 8).



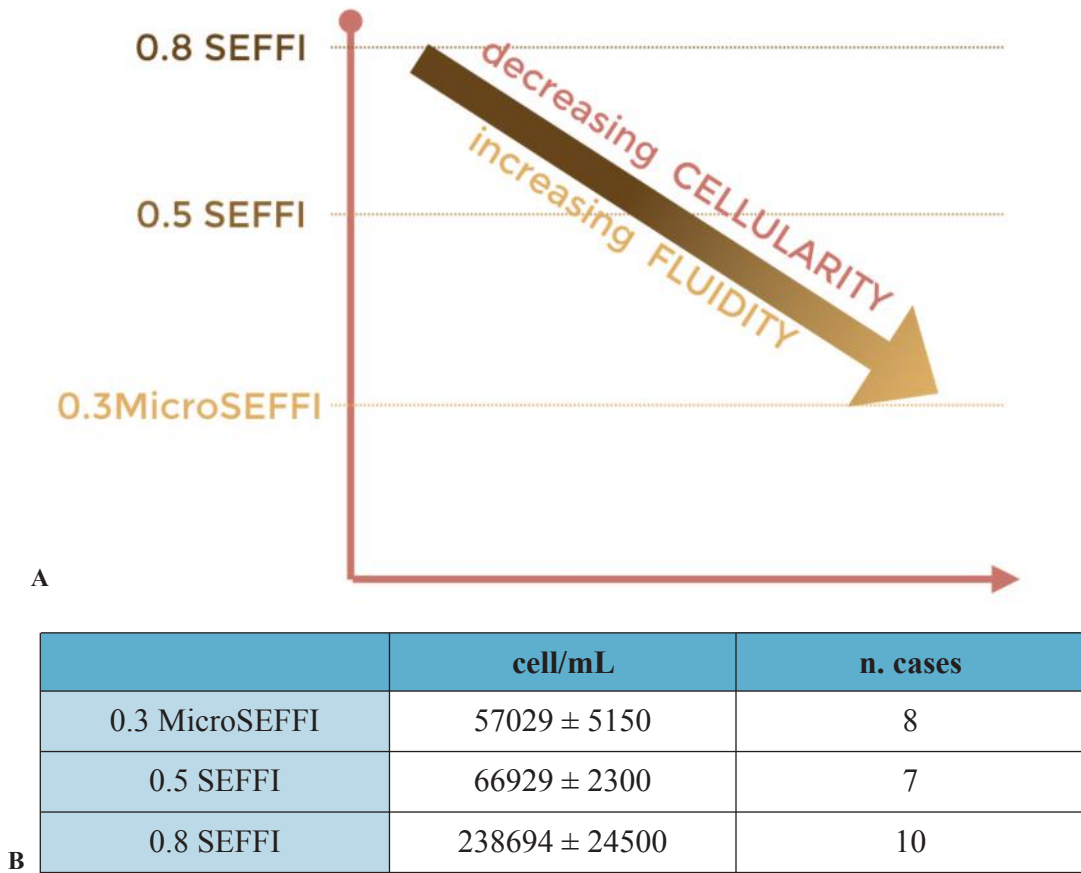
**Figure 5. A-B,** The enhancement with PRP 20% increased the cell growth in both the tissue samples harvested with the SEFFI (0.5 mm) and the Micro-SEFFI (0.3 mm) harvesting procedures.



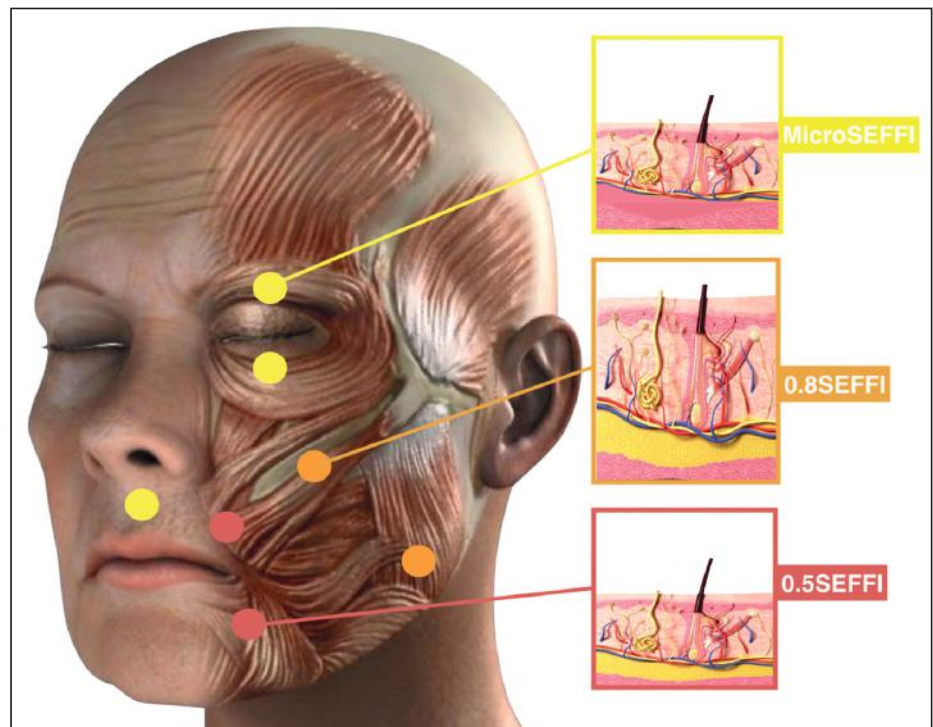
A

TISSUE	Number of cells	P-value
0.3 M-SEFFI centrifugated	1.87 x 10 <sup>5</sup>	.014
0.3 M-SEFFI centrifugated + PRP	3.22 x 10 <sup>5</sup>	
0.5 SEFFI centrifugated	5.10 x 10 <sup>5</sup>	.038
0.5 SEFFI centrifugated + PRP	6.25 x 10 <sup>5</sup>	

B



**Figure 6.** A-B, The cellularity (cell/mL) of the SVF fraction of the harvested tissue decreases with decreasing size of the side portholes; the fluidity of the tissue preparation, instead increases when the processing is done through smaller holes.



**Figure 7.** In SEFFI and MicroSEFFI techniques, we perform subdermal injections of the different tissue preparations in the different areas, according to the thickness of the skin and subcutaneous tissue.

Side-port holes diameter (mm)	Average time to harvest 10cc
0.8	1'24"
0.5	4'15"
0.3	14'35"

**Figure 8.** The average harvesting time of 10 mL of tissue using different harvesting cannulas, depending on the size of the side port holes.

No intraoperative complications were recorded, including indurations, cysts, infections or any serious complications such as necrosis or fat emboli due to intravascular injection<sup>43</sup>. No postoperative complications were recorded including irregularities or lumpiness. Average follow-up was 4.1 months (range 1-6 months).

A satisfaction survey was submitted to the senior surgeons and to the patients to evaluate clinical assessment and patient satisfaction: we received the results of the survey after 1, 3, 6 months from 93 patients. This survey was aimed at evaluating the perceived face volume restoration and skin rejuvenation after 1 month, 3 months and 6 months post surgical operation.

The following questionnaire was filled out by the patients and by the surgeon:

- How do you evaluate the degree of volume restoration after treatment?
- How do you evaluate the degree of skin quality enhancement after treatment?
- How do you evaluate the degree of overall rejuvenation of your face after treatment?

The patients and the surgeons indicated one of the following scores for each question:

1. No result; 2. Moderate result; 3. Good result; 4. Optimum result. Responses were collected, anonymized and analyzed in aggregate form.

The survey outcome is reported in Figure 9.

## DISCUSSION

When performing an autologous fat graft, three steps are required to complete the procedure: a. Harvesting, b. Manipulation and preparation, c. Implantation/injection.

These three steps should be given careful attention to maximize the volumizing and regenerating action of the implanted tissue.

## HARVESTING (A)

In our opinion, the harvesting method is critical for the procedure of autologous fat grafting in facial rejuvenation. The size of the cannula affects the amount of tissue that can be harvested, and the size of the side port holes determines the size of the tissue lobules generated. The characteristics of the harvesting cannula will impact the degree of manipulation required to make the tissue fluid enough to be injected superficially.

ASCs are found in the SVF, and they occur with higher frequency in adipose tissue with a higher density of blood vessels<sup>44-46</sup>. Since the density of blood vessels is more elevated in the most superficial layers<sup>47</sup>, harvesting the adipose tissue in the subdermal layer guarantees the highest concentration of blood vessels, hence of SVF, hence of ASCs. The diameter of conventional liposuction cannulas is of 4-6 mm, and it is our opinion that this can lead to the appearance of skin irregularities. A harvesting microcannula with inner diameter  $\leq 2$  mm (according to Klein's definition, see <sup>48</sup>) is used for the harvesting of adipose tissue from the superficial layer so that the appearance of skin irregularities will be minimized. Trivisonno et al<sup>49</sup> processed an equal volume of freshly isolated lipoaspirate with either a microcannula (blunt tip, 170 mm long, 2 mm  $\varnothing$ , 5 ports, single port  $\varnothing$  1 mm) or a standard liposuction cannula (blunt tip, 170 mm long, 3 mm  $\varnothing$ , single port  $\varnothing$  3  $\times$  9 mm). The total number of cells isolated from the microcannula-harvested samples was significantly higher (approximately 2-fold) than the number of cells isolated from samples collected with the standard liposuction cannula ( $p = 0.04$ ). Nguyen et al<sup>23</sup> conducted a comparative study on mice using two different harvesting cannulas: the Coleman standard harvesting cannula (2 mm hole diameter) (BYRON) and a multi-perforated cannula with holes of 1 mm in diameter (PLA 155 Poret). This study aimed to obtain a tissue injectable in the superficial plane with a 23-25G (0.5-0.6 mm) microcannula, instead of the 17G (1.5 mm) standard Coleman injecting cannula. The immediate histologic analysis showed adipose tissue presenting a normal structure. The average size of the fat lobules varied from 500 microns to 1000 microns versus a size exceeding 1000 microns with Coleman's technique. This smaller size facilitates fat transfer using a 1cc syringe fit with 23G and 25G cannulas. The objective of microinjection of adipose tissue



**Figure 9.** A satisfaction survey was submitted to senior surgeons and 93 patients. This survey was aimed at evaluating the perceived face volume restoration and skin rejuvenation after 1 month, 3 months and 6 months. Score: 1. No result; 2. Moderate result; 3. Good result; 4. Optimum result. The table indicates the average scores reported.

	Patient 1 month post op	Surgeon 1 month post op	Patient 3 months post op	Surgeon 3 months post op	Patient 6 months post op	Surgeon 6 months post op
Volume enhancement	3.68	3.42	3.25	3.14	2.95	3.23
skin quality improve	2.55	2.8	2.87	3.2	3.55	3.83
facial rejuvenation	3.55	3.2	3.43	3.53	3.62	3.12

(performed by using small microcannulas) is to enable transfer without obturation at the subdermal level. The same would be impossible with the Coleman cannulas of 17G. We compared the adipose tissue preparations harvested with three different cannulae: Coleman standard harvesting cannula (2 mm hole diameter) (BYRON), SEFFI 0.5 side ports holes cannula, SEFFI 0.8 side ports holes cannula (27). Hematoxylin and eosin stainings showed mature viable adipocytes, with intact cell walls and visible nuclei equally represented in the three specimens. A well-represented stromal component was noted between adipocytes, without signs of cell necrosis (Figure 11).

The adipocyte size ranged from 0.03 mm to 0.13 mm and was independent of the size of the harvesting cannula. Alamar Blue testing demonstrated that SVF cells from the three samples had a similar growth rate and an equal tendency to differentiate into mature adipocytes after being placed in the induction medium. During the differentiation process into mature adipocytes, the cells derived from the smaller side-port cannulas showed a reduced tendency to form aggregates (Figure 12).

In our subsequent study focused on MicroSEFFI<sup>28</sup>, we compared the harvested tissues obtained via the SEFFI 0.5 side ports holes cannula and the MicroSEFFI 0.3 side ports holes: we detected mature, viable adipocytes, with intact cell walls and visible nuclei. A well-represented stromal component was noted between adipocytes, without signs of cell necrosis (Figure 11A). The adipocyte size ranged from 0.04 mm to 0.18 mm. The number

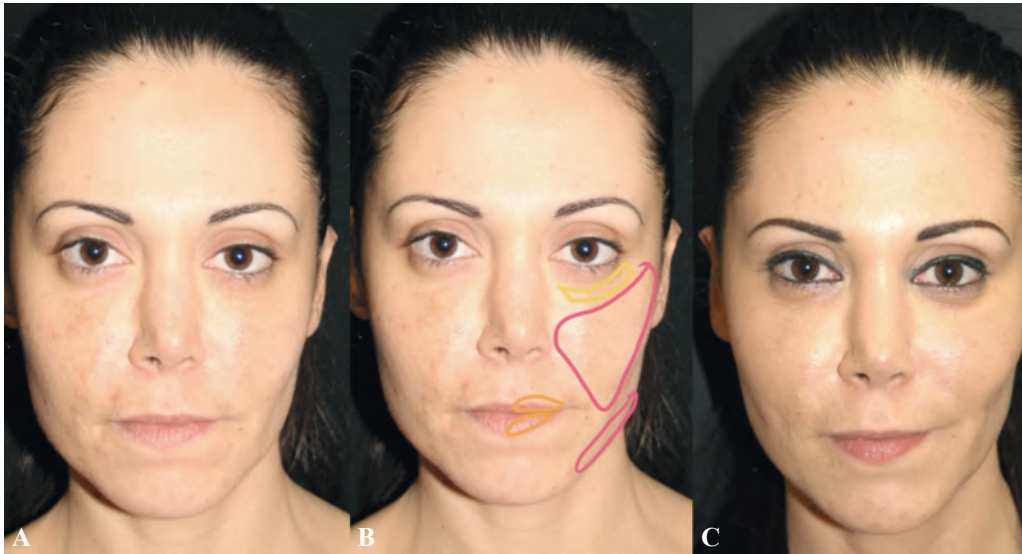of cells obtained from harvesting with the 0.3 mm diameter ports was lower as compared to that obtained from the 0.5 mm diameter ports. The addition of PRP stimulated an increase in the growth rate of the cells obtained via the 0.3 mm ports (Figure 5b).

SEFFI (side portholes of 0.8 mm and 0.5 mm) and MicroSEFFI (side port holes of 0.3 mm) harvesting techniques provide three different kinds of adipose tissue preparations: these preparations display a decreasing cellularity and increasing fluidity as the side port holes size decreases (Figure 6A, 6B).

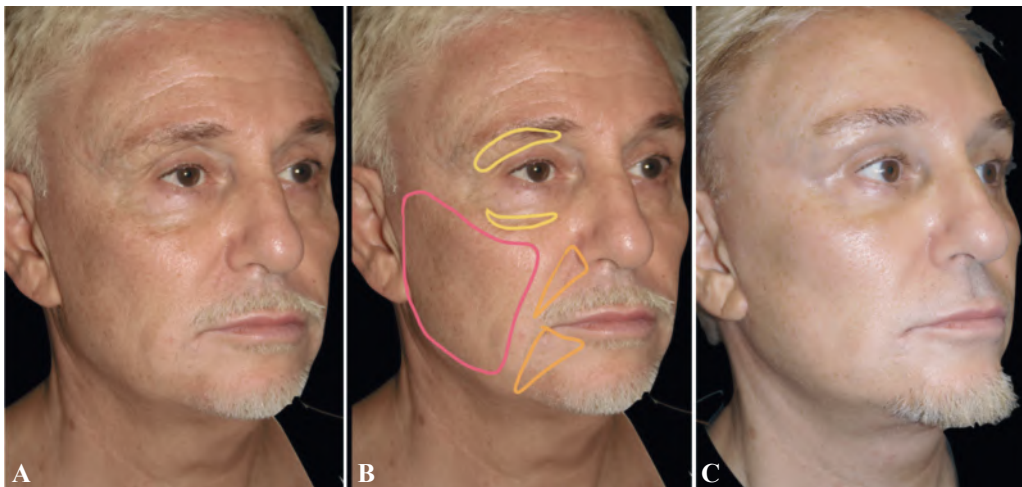
#### **MANIPULATION AND PREPARATION (B)**

The harvested tissue consists of viable adipocytes and SVF containing several different cell types. Among the cell types residing in the SVF, pericytes, and ASCs are considered to be the most important for regenerative purposes. Pericytes are cells that constitute the outer walls of blood vessels, surrounding and wrapping the layer of endothelial cells. After trauma, pericytes activate and transform into ASCs<sup>50,51</sup>. Tremolada et al<sup>50,51</sup> showed that after injection, the MSCs begin to produce a complex and heterogeneous spectrum of bioactive molecules, which are secreted in exosomes and act in a paracrine fashion in the surrounding environment.

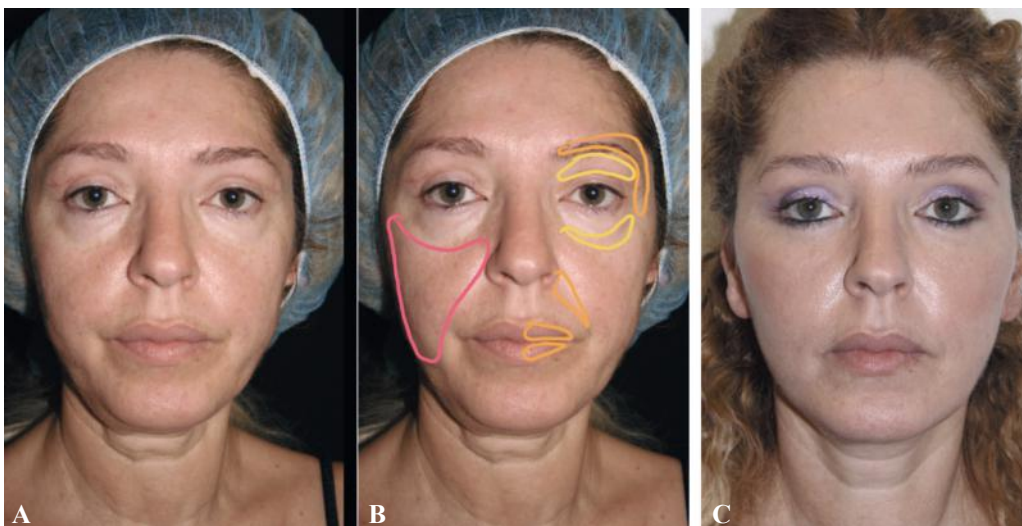
Viable adipocytes, pericytes, and ASCs are key for the success of regenerative plastic, reconstructive, and aesthetic surgical strategies. Hence, their manipulation must be extremely delicate, to maximize viability and engraftment.



**Figure 10. Case 1.** 31 years old woman who underwent SEFFI and Micro SEFFI. *A*, Pre-treatment; *B*, Preoperative plan (yellow MicroSEFFI, brown 0.5 SEFFI, and red 0.8 SEFFI); *C*, 6 months post-treatment.

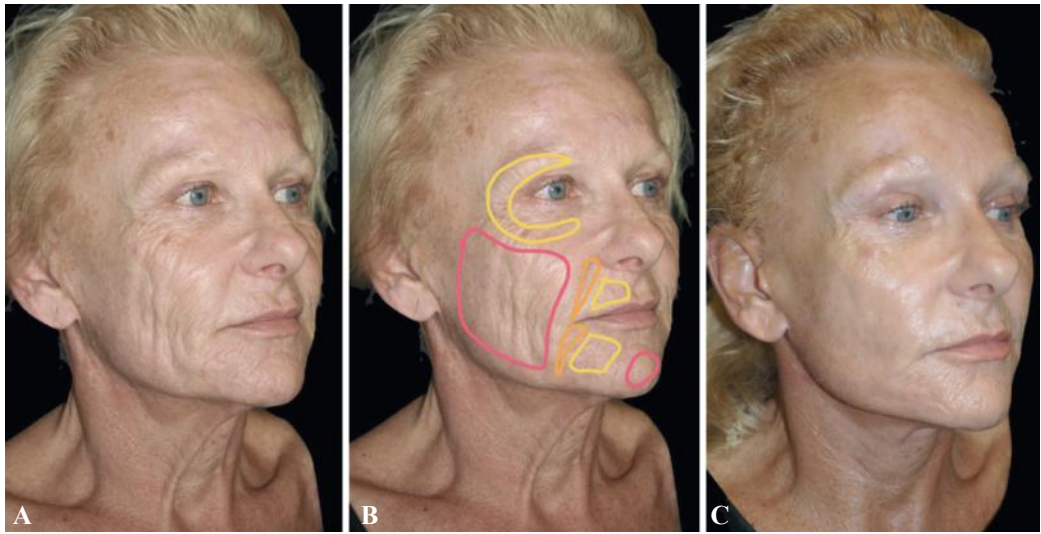


**Figure 10. Case 2.** 53 years old man who underwent R3 rejuvenation. *A*, Pre-treatment; *B*, Preoperative plan (yellow MicroSEFFI, brown 0.5 SEFFI, and red 0.8 SEFFI); *C*, 6 months post-treatment.

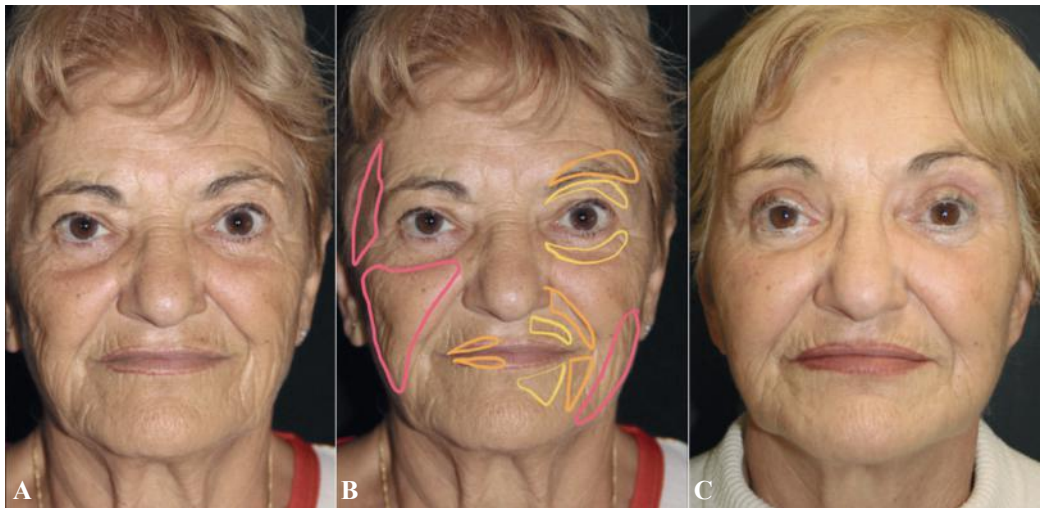


**Figure 10. Case 3.** 48 years old woman who underwent R3 rejuvenation. *A*, Pre-treatment; *B*, Preoperative plan (yellow MicroSEFFI, brown 0.5 SEFFI, and red 0.8 SEFFI); *C*, 4 months post-treatment.

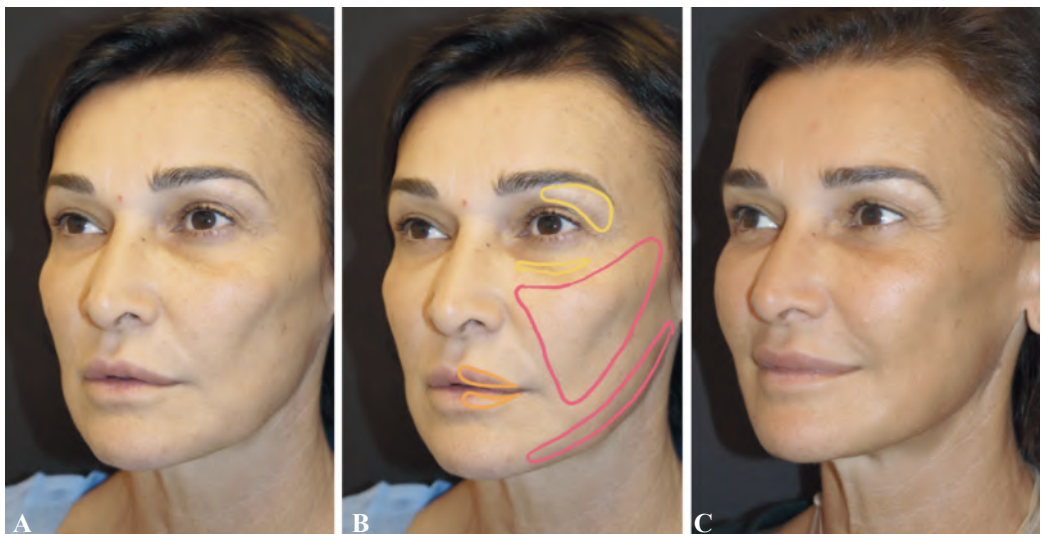**Figure 10. Case 4.** 56 years old woman who underwent R3 rejuvenation. *A*, Pre-treatment; *B*, Preoperative plan (yellow MicroSEFFI, brown 0.5 SEFFI, and red 0.8 SEFFI); *C*, 6 months post-treatment.

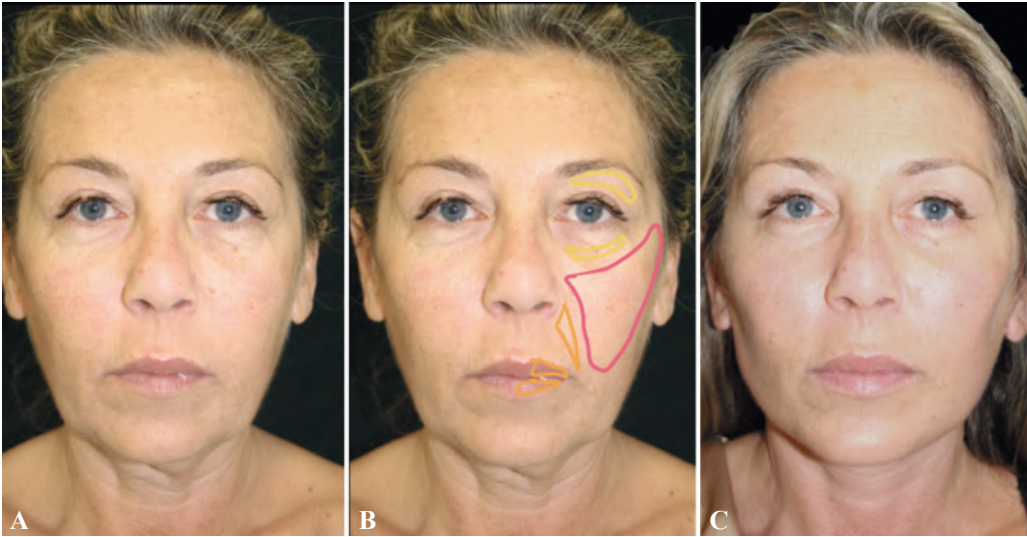

**Figure 10. Case 5.** 65 years old woman who underwent R3 rejuvenation and upper blepharoplasty. *A*, Pre-treatment; *B*, Preoperative plan (yellow MicroSEFFI, brown 0.5 SEFFI, and red 0.8 SEFFI); *C*, 6 months post-treatment.

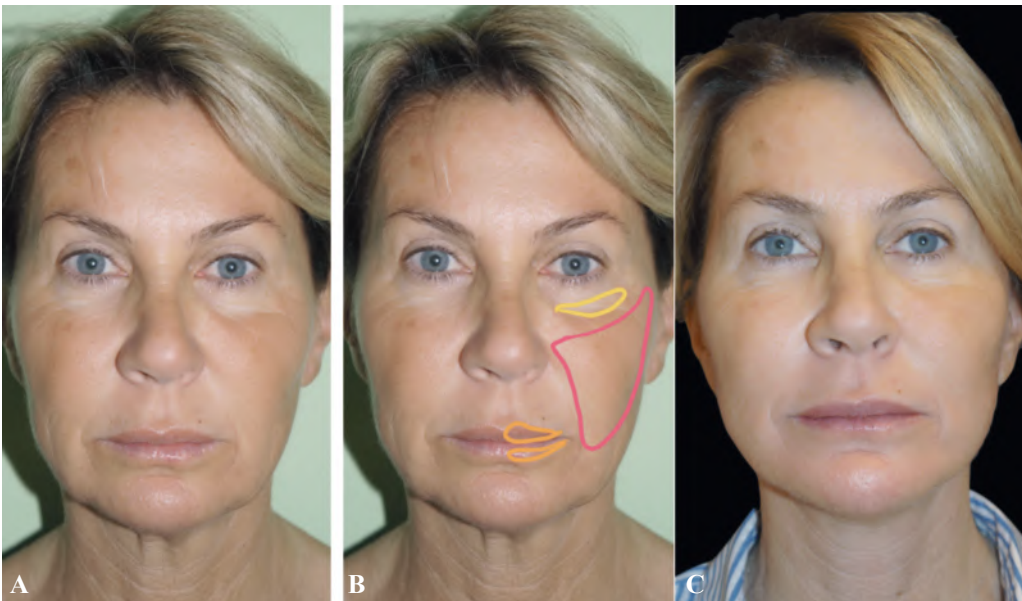

**Figure 10. Case 6.** 42 years old woman who underwent SEFFI, MicroSEFFI. *A*, Pre-treatment; *B*, Preoperative plan (yellow MicroSEFFI, brown 0.5 SEFFI, and red 0.8 SEFFI); *C*, 6 months post-treatment.

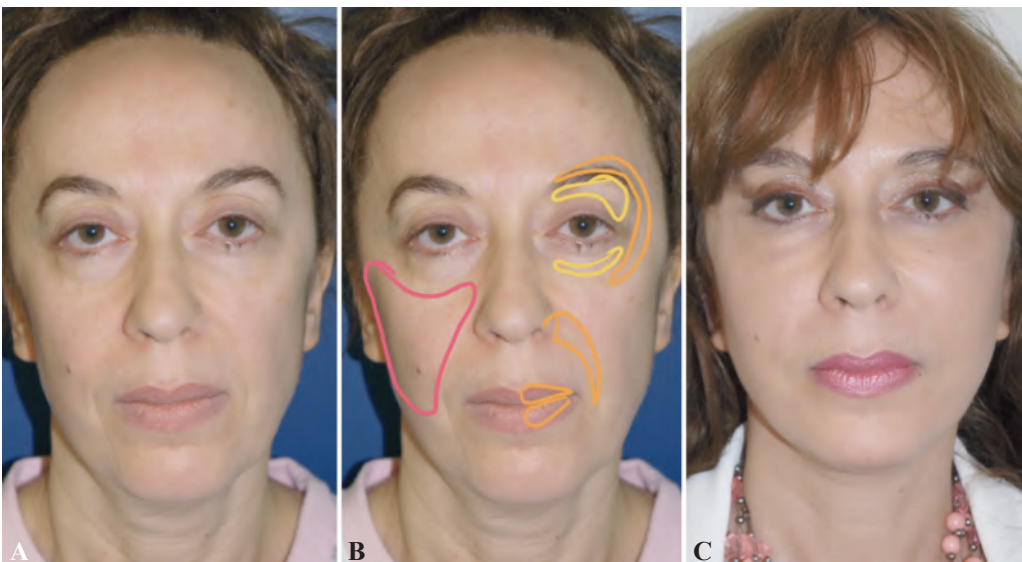



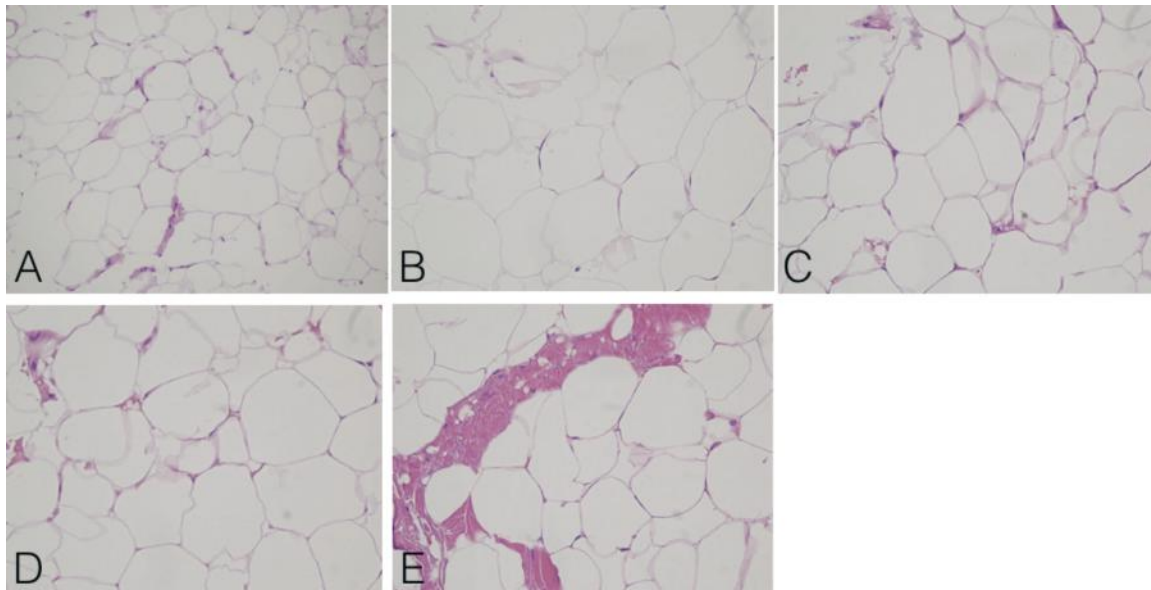
**Figure 10. Case 7.** 51 years old woman who underwent SEFFI, MicroSEFFI and neck lift. *A*, Pre-treatment; *B*, Preoperative plan (yellow MicroSEFFI, brown 0.5 SEFFI, and red 0.8 SEFFI); *C*, 6 months post-treatment.



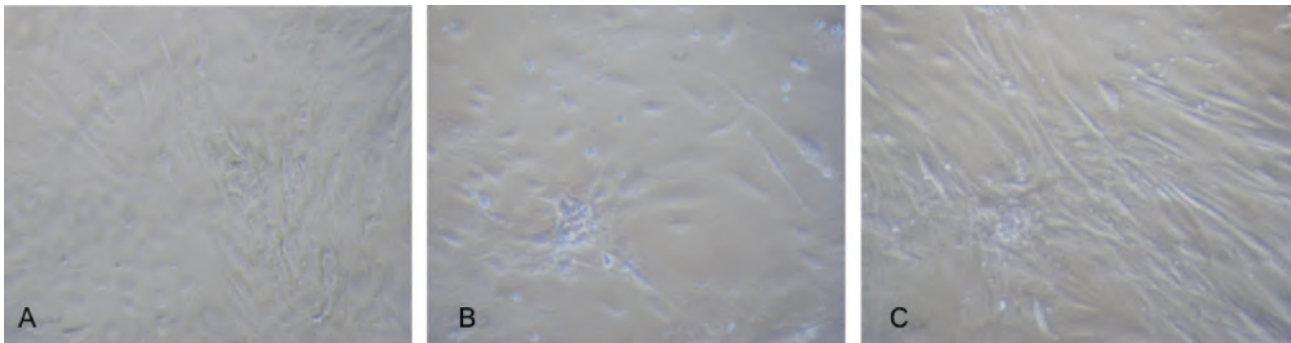
**Figure 10. Case 8.** 52 years old woman who underwent SEFFI, MicroSEFFI and neck lift. *A*, Pre-treatment; *B*, Preoperative plan (yellow MicroSEFFI, brown 0.5 SEFFI, and red 0.8 SEFFI); *C*, 6 months post-treatment.



**Figure 10. Case 9.** 48 years old woman who R3 rejuvenation. *A*, Pre-treatment; *B*, Preoperative plan (yellow MicroSEFFI, brown 0.5 SEFFI, and red 0.8 SEFFI); *C*, 6 months post-treatment.



**Figure 11.** Hematoxylin and eosin staining (40X magnification) of adipose tissue samples processed with four different cannulae. Samples were obtained with 0.3 side-holes cannula (A); 0.5 side-holes cannula (B); 0.8 side-holes cannula (C); Coleman's cannula (D). Mature adipocytes display features of viability (intact cell walls with visible nuclei) in the absence of signs of cell necrosis. E, The stromal component between adipocytes is well represented. A normal microvascular pattern is visible in all the specimens. 317x237 mm (72 x 72 DPI).



**Figure 12.** Phase contrast microscopy of the three different samples 0.5 side-holes cannula (A); 0.8 side-holes cannula (B); Coleman's cannula (C) showing that SVF cell line derived from the smaller side-holes cannula (in A) have a reduced tendency to form aggregate. 361x98 mm (72 x 72 DPI).

Manipulation of the harvested tissue has three main objectives: 1) to rinse the tissue, in order to wash away the local anesthetic which could compromise cellular viability<sup>33</sup>; 2) to concentrate the tissue, typically via centrifugation; 3) to fluidify the tissue preparation, enabling injection into the dermal and subdermal layer, maximizing the yield of adipocyte engraftment and the effect of skin regeneration. This last step is the most sensitive, as in this stage tissue and cell viability is most likely damaged by manipulation. Tremolada et al showed that enzymatic manipulation of the tissue not only destroys the viable adipocytes, but also causes the

digestion of the extracellular matrix surrounding the cells, possibly affecting cell secretory functions. The digestion might also damage the cells, affecting cell function and viability. The enzymatic method may be too aggressive and might destroy exosomes during processing. For fluidization of the tissue before implantation, several mechanical procedures have been proposed. In the Nanofat procedure, Tonnard et al<sup>52</sup> provide for the tissue to be emulsified, i.e. harvested with 3 mm multiport cannula, equipped with several sharp side holes of 1 mm diameter. Processed tissue is made fluid enough to be injected with a 27G needle in the

dermal and subdermal layer of particularly delicate areas like the periocular and perioral ones. Tonnard et al<sup>52</sup> emphasized that the Nanofat procedure does not contain viable adipocytes. Hence, its effect should be exclusively regenerative. A recent study by Rossi et al<sup>53</sup> compared the cells isolated from adipose tissue processed with the Nanofat procedure, versus the standard Coleman procedure. The group concluded that the Nanofat procedure does not impact negatively the multilineage differentiation potential and immunomodulatory properties of the ASC population.

In the Sharp-Needle Intradermal Fat Grafting (SNIF), Zeltzer et al<sup>24</sup> harvested the tissue with a multiport sharp cannula, 2 mm in diameter, with holes of 1 mm in diameter (Tulip Medical Products, San Diego, CA, USA). In this case, manipulation consists in rinsing the tissue with a normal saline solution over a sterile nylon cloth with 0.5 mm mesh size. The tissue is then injected into a superficial dermal layer with a needle not smaller than 23G (0.6 mm); this tissue undergoes a minimal manipulation, but the fluidity only permits the superficial injection in the perioral area where the skin is thicker than in periocular area. In this case, a minimal manipulation leads to the preparation of a less fluid tissue which should be injected superficially only in the perioral area. Moreover, in the study on the SNIF technique, there is no evidence of the viability of the adipocytes and of the amount of SVF/ASCs.

Other mechanical systems have been proposed for the purpose of reducing the fat clusters in size, such as rotating blades (e.g. blenders) which turned out to be very traumatic to cells and produce large amounts of oil residues and cellular debris<sup>54</sup>. Tremolada et al<sup>50</sup> developed a device (LIPOGEM<sup>®</sup>) aimed to mechanically obtain small adipose clusters from a tissue harvested via a disposable 19 cm blunt cannula (3 mm OD), with 5 oval holes (1x2 mm). Extremely fast and easy to use, this device produces fluid tissue by pushing it through 2 different cutting hexagonal filters so as to obtain spheroidal adipose clusters with a diameter of 1-3.5 mm to clusters of 0.2-0.8 mm<sup>51</sup>. The study showed that the tissue obtained via LIPOGEM<sup>®</sup> contains viable adipocytes and a high percentage of mature pericytes and mesenchymal stem cells (MSCs). The tissue obtained via LIPOGEM<sup>®</sup> processing has the same fluidity of SEFFI 0.8. Hence, it has the same indication of use in facial treatment. In our hands, LIPOGEM<sup>®</sup>-processed tissue did not result

optimal for superficial injection in delicate areas like the periocular and perioral area due to the risk of visibility and lumpiness.

### *IMPLANTATION/INJECTION (C)*

Clearly, the implantation technique is strictly dependent on the previous steps of harvesting and manipulation. The objective here is to obtain adipose tissue clusters that are small enough to be appropriate for implantation and engraftment in sites as superficial as possible.

Coleman has standardized his Lipostructure<sup>®</sup> technique<sup>3,55</sup> for grafting fat and SVF/ASCs in various regions of the body and the face. Such technique provided for implantation through the 17G cannula and proved to deliver a good volumizing effect and a good degree of engraftment. Nguyen et al<sup>23</sup> compared implanting adipose tissue in rats by use of Coleman's technique (aspiration with 3 mm side port hole cannula) against 1 mm side port hole cannula lipoaspirate. Such study revealed a higher percentage of engraftment (78% against 70%) of the tissue harvested according to Coleman's technique at the expense of its fluidity. In facial treatments, such lower fluidity determines the requirement to use a 17G (1.15 mm) cannula for implantation. It also requires that the tissue injection is performed deeper in delicate areas like the periocular and perioral areas.

In the Sharp-Needle Intradermal Fat Grafting (SNIF), Zeltzer et al<sup>24</sup> inject the tissue superficially by use of a 23G needle (0.6 mm) only in the perioral area; no superficial treatment of the periocular area is described.

In the Nanofat technique, the group of Tonnard et al<sup>52</sup> has succeeded in obtaining an extremely fluid tissue by emulsification. This tissue can be easily injected with a 27G needle (0.4 mm) superficially in all areas of the face with no risk of skin irregularities: such tissue, however, is deprived of viable adipocytes hence it has no immediate volumizing effect.

Tremolada et al<sup>50,56</sup> via LIPOGEM<sup>®</sup> obtained a tissue with a good fluidity which should be injected with a microcannula of 20-21G (0.9-0.8 mm). This tissue has a fluidity comparable to SEFFI 0.8. Hence, it should be injected superficially (subdermal) only in the areas of the face with thicker skin. Examples of such areas include the malar and zygomatic area, temporal area, mandibular arch, and chin. It should be injected deeper, under the muscle, in the areas with thin skin and no subcutaneous tissue like the periocular and perioral area.

## CONCLUSIONS

The loss of volume and the aging of the tissue are the two most important causes of facial aging in patients from 45 to 55 years old. The autologous fat graft is today the most promising procedure for facial rejuvenation. In the adipose tissue, the adipocytes address volume restoration while the SVF (with pericytes and ASCs) is involved in tissue regeneration. The face has a very complex pattern to treat. Some areas need more volume restoration than regeneration, others more regeneration than restoration. Further, the skin greatly differs in thickness depending on areas and patients. The golden rule in facial tissue graft is to inject as superficially as possible so as to increase tissue engraftment and to enhance the regenerative effect. SEFFI and MicroSEFFI represent our proposal for microfat graft in facial rejuvenation procedures. The SEFFI and MicroSEFFI techniques only require minimal manipulation of the tissue, they do not need any device and provide three different tissues with different degrees of cellularity and fluidity, which can be injected superficially in different areas of the face without any risk of irregularity and lumpiness.

## CONFLICT OF INTERESTS:

The Authors declare that they have no conflict of interests.

## REFERENCES

- Gennai A, Bernardini FP. R3 facial rejuvenation through minimal incisions vertical endoscopic lifting (MIVEL) and superficial enhanced fluid fat injection (SEFFI): endoscopic repositioning, tissue regeneration, volume restoration. *Aesthetic Med* 2015; 1(21): 54-60.
- Coleman SR. Long-term survival of fat transplants: controlled demonstrations. *Aesthetic Plast Surg* 1995; 19(5): 421-425.
- Coleman SR. Facial recontouring with lipostructure. *Clin Plast Surg* 1997; 24(2): 347-367.
- Coleman SR. Structural fat grafts: the ideal filler? *Clin Plast Surg* 2001; 28(1): 111-119.
- Coleman SR. Structural fat grafting: more than a permanent filler. *Plast Reconstr Surg* 2006; 118(3 Suppl): 108S-120S.
- James IB, Coleman SR, Rubin JP. Fat, stem cells, and platelet-rich plasma. *Clin Plast Surg* 2016; 43(3): 473-488.
- Zuk PA, Zhu M, Mizuno H, Huang J, Futrell JW, Katz AJ, Benhaim P, Lorenz HP, Hedrick MH. Multilineage cells from human adipose tissue: implications for cell-based therapies. *Tissue Eng* 2001; 7(2): 211-228.
- Zuk PA, Zhu M, Ashjian P, De Ugarte DA, Huang JI, Mizuno H, Alfonso ZC, Fraser JK, Benhaim P, Hedrick MH. Human adipose tissue is a source of multipotent stem cells. *Mol Biol Cell* 2002; 13(12): 4279-4295.
- Zuk PA. The adipose-derived stem cell: looking back and looking ahead. *Mol Biol Cell* 2010; 21(11): 1783-1787.
- Crisan M, Yap S, Casteilla L, Chen CW, Corselli M, Park TS, Andriolo G, Sun B, Zheng B, Zhang L, Norotte C, Teng PN, Traas J, Schugar R, Deasy BM, Badylak S, Buhning HJ, Giacobino JP, Lazzari L, Huard J, Péault B. A perivascular origin for mesenchymal stem cells in multiple human organs. *Cell Stem Cell* 2008; 3(3): 301-313.
- Tallone T, Realini C, Bohmler A, Kornfeld C, Vassalli G, Moccetti T, Bardelli S, Soldati G. Adult human adipose tissue contains several types of multipotent cells. *J Cardiovasc Transl Res* 2011; 4(2): 200-210.
- Huang JI, Beanes SR, Zhu M, Lorenz HP, Hedrick MH, Benhaim P. Rat extramedullary adipose tissue as a source of osteochondrogenic progenitor cells. *Plast Reconstr Surg* 2002; 109(3): 1033-1041; discussion 42-43.
- Fraser JK, Schreiber R, Strem B, Zhu M, Alfonso Z, Wulur I, Hedrick MH. Plasticity of human adipose stem cells toward endothelial cells and cardiomyocytes. *Nat Clin Pract Cardiovasc Med* 2006; 3 Suppl 1: S33-37.
- Caplan AI. Adult mesenchymal stem cells for tissue engineering versus regenerative medicine. *J Cell Physiol* 2007; 213(2): 341-347.
- Caplan AI, Dennis JE. Mesenchymal stem cells as trophic mediators. *J Cell Biochem* 2006; 98(5): 1076-1084.
- Blaber SP, Webster RA, Hill CJ, Breen EJ, Kuah D, Vesey G, Herbert BR. Analysis of in vitro secretion profiles from adipose-derived cell populations. *J Transl Med* 2012; 10: 172.
- Li K, Li F, Li J, Wang H, Zheng X, Long J, Guo W, Tian W. Increased survival of human free fat grafts with varying densities of human adipose-derived stem cells and platelet-rich plasma. *J Tissue Eng Regen Med* 2017; 11(1): 209-219.
- Sultan SM, Barr JS, Butala P, Davidson EH, Weinstein AL, Knobel D, Saadeh PB, Warren SM, Coleman SR, Hazen A. Fat grafting accelerates revascularisation and decreases fibrosis following thermal injury. *J Plast Reconstr Aesthet Surg* 2012; 65(2): 219-227.
- Del Papa N, Di Luca G, Sambataro D, Zaccara E, Maglione W, Gabrielli A, Fraticelli P, Moroncini G, Beretta L, Santaniello A, Sambataro G, Ferraresi R, Vitali C. Regional implantation of autologous adipose tissue-derived cells induces a prompt healing of long-lasting indolent digital ulcers in patients with systemic sclerosis. *Cell Transplant* 2015; 24(11): 2297-2305.
- Rigotti G, Marchi A, Galie M, Baroni G, Benati D, Krampera M, Pasini A, Sbarbati A. Clinical treatment of radiotherapy tissue damage by lipoaspirate transplant: a healing process mediated by adipose-derived adult stem cells. *Plast Reconstr Surg* 2007; 119(5): 1409-1422; discussion 23-24.
- Mojallal A, Lequeux C, Shipkov C, Breton P, Foyatier JL, Braye F, Damour O. Improvement of skin quality after fat grafting: clinical observation and an animal study. *Plast Reconstr Surg* 2009; 124(3): 765-774.
- Sterodimas A, de Faria J, Nicaretta B, Pitanguy I. Tissue engineering with adipose-derived stem cells (ADSCs): current and future applications. *J Plast Reconstr Aesthet Surg* 2010; 63(11): 1886-1892.

23. Nguyen PS, Desouches C, Gay AM, Hautier A, Magalon G. Development of micro-injection as an innovative autologous fat graft technique: the use of adipose tissue as dermal filler. *J Plast Reconstr Aesthet Surg* 2012; 65(12): 1692-1699.
24. Zeltzer AA, Tonnard PL, Verpaele AM. Sharp-needle intradermal fat grafting (SNIF). *Aesthet Surg J* 2012; 32(5): 554-561.
25. Bourne DA, James IB, Wang SS, Marra KG, Rubin JP. The Architecture of Fat Grafting: What Lies beneath the Surface. *Plast Reconstr Surg* 2016; 137(3): 1072-1079.
26. Bernardini FP, Gennai A, Izzo L, Zambelli A, Repaci E, Baldelli I, et al. Superficial Enhanced Fluid Fat Injection (SEFFI) to correct volume defects and skin aging of the face and periorcular region. *Aesthet Surg J* 2015; 35(5): 504-515.
27. Bernardini FP, Gennai A. Fluid fat injection for volume restoration and skin regeneration of the periorcular aesthetic unit. *JAMA Facial Plast Surg* 2016; 18(1): 68-70.
28. Gennai A, Zambelli A, Repaci E, Quarto R, Baldelli I, Fraternali G, Bernardini FP. Skin rejuvenation and volume enhancement with the Micro Superficial Enhanced Fluid Fat Injection (M-SEFFI) for skin aging of the periorcular and perioral regions. *Aesthet Surg J* 2017; 37(1): 14-23.
29. Bernardini FP, Gennai A, Izzo L, Devoto MH. Minimal incisions vertical endoscopic lifting and fat grafting as a systematic approach to the rejuvenation of the periorcular esthetic unit. *Ophthal Plast Reconstr Surg* 2013; 29(4): 308-315.
30. Gennai A. *Endochirurgia estetica del volto: SEE Editrice, Firenze, 2011.*
31. Gennai A, Saponaro A, Iozzo I. El rol del lifting endoscópico fronto-témporo-orbitario en el nuevo concepto de rejuvenecimiento facial: mini-invasivo, tensión moderada, restauración de volúmenes. The importance of brow-temporal-orbital endoscopic facelift in the new concept of facial rejuvenation: low invasiveness, moderate tension, volume restoration. *Cirurgia Plástica Ibero-Latinoamericana*, 2009; pp. 27-34.
32. Gentile P, Orlandi A, Scioli MG, Di Pasquali C, Bocchini I, Cervelli V. Concise review: adipose-derived stromal vascular fraction cells and platelet-rich plasma: basic and clinical implications for tissue engineering therapies in regenerative surgery. *Stem Cells Transl Med* 2012; 1(3): 230-236.
33. Girard AC, Atlan M, Bencharif K, Gunasekaran MK, Delarue P, Hulard O, Lefebvre-d'Hellencourt C, Roche R, Hoareau L, Festy F. New insights into lidocaine and adrenaline effects on human adipose stem cells. *Aesthetic Plast Surg* 2013; 37(1): 144-152.
34. Li F, Guo W, Li K, Yu M, Tang W, Wang H, Tian W. Improved fat graft survival by different volume fractions of platelet-rich plasma and adipose-derived stem cells. *Aesthet Surg J* 2015; 35(3): 319-333.
35. Rigotti G, Charles-de-Sa L, Gontijo-de-Amorim NF, Takiya CM, Amable PR, Borojevic R, Benati D, Bernardi P, Sbarbati A. Expanded stem cells, stromal-vascular fraction, and platelet-rich plasma enriched fat: comparing results of different facial rejuvenation approaches in a clinical trial. *Aesthet Surg J* 2016; 36(3): 261-270.
36. Gentile P, Scioli MG, Bielli A, Orlandi A, Cervelli V. Concise review: the use of adipose-derived stromal vascular fraction cells and platelet rich plasma in regenerative plastic surgery. *Stem Cells* 2017; 35(1): 117-134.
37. Liao HT, Marra KG, Rubin JP. Application of platelet-rich plasma and platelet-rich fibrin in fat grafting: basic science and literature review. *Tissue Eng Part B Rev* 2014; 20(4): 267-276.
38. Cervelli V, Scioli MG, Gentile P, Doldo E, Bonanno E, Spagnoli LG, Orlandi A. Platelet-rich plasma greatly potentiates insulin-induced adipogenic differentiation of human adipose-derived stem cells through a serine/threonine kinase Akt-dependent mechanism and promotes clinical fat graft maintenance. *Stem Cells Transl Med* 2012; 1(3): 206-220.
39. Liao HT, James IB, Marra KG, Rubin JP. The effects of platelet-rich plasma on cell proliferation and adipogenic potential of adipose-derived stem cells. *Tissue Eng Part A* 2015; 21(21-22): 2714-2722.
40. Tajima S, Tobita M, Orbay H, Hyakusoku H, Mizuno H. Direct and indirect effects of a combination of adipose-derived stem cells and platelet-rich plasma on bone regeneration. *Tissue Eng Part A* 2015; 21(5-6): 895-905.
41. Oh DS, Cheon YW, Jeon YR, Lew DH. Activated platelet-rich plasma improves fat graft survival in nude mice: a pilot study. *Dermatol Surg* 2011; 37(5): 619-625.
42. Cervelli V, Gentile P, De Angelis B, Calabrese C, Di Stefani A, Scioli MG, Curcio BC, Felici M, Orlandi A. Application of enhanced stromal vascular fraction and fat grafting mixed with PRP in post-traumatic lower extremity ulcers. *Stem Cell Res* 2011; 6(2): 103-111.
43. Lazzeri D, Agostini T, Figus M, Nardi M, Pantaloni M, Lazzeri S. Blindness following cosmetic injections of the face. *Plast Reconstr Surg* 2012; 129(4): 995-1012.
44. Zannettino AC, Paton S, Arthur A, Khor F, Itescu S, Gimble JM, Gronthos S. Multipotential human adipose-derived stromal stem cells exhibit a perivascular phenotype in vitro and in vivo. *J Cell Physiol* 2008; 214(2): 413-421.
45. Cai X, Lin Y, Hauschka PV, Grottkau BE. Adipose stem cells originate from perivascular cells. *Biol Cell* 2011; 103(9): 435-447.
46. Corselli M, Chen CW, Crisan M, Lazzari L, Peault B. Perivascular ancestors of adult multipotent stem cells. *Arterioscler Thromb Vasc Biol* 2010; 30(6): 1104-1109.
47. El-Mrakby HH, Milner RH. Bimodal distribution of the blood supply to lower abdominal fat: histological study of the microcirculation of the lower abdominal wall. *Ann Plast Surg* 2003; 50(2): 165-170.
48. Klein JA. Tumescence technique chronicles. Local anesthesia, liposuction, and beyond. *Dermatol Surg* 1995; 21(5): 449-457.
49. Trivisonno A, Di Rocco G, Cannistra C, Finocchi V, Torres Farr S, Monti M, Toietta G. Harvest of superficial layers of fat with a microcannula and isolation of adipose tissue-derived stromal and vascular cells. *Aesthet Surg J* 2014; 34(4): 601-613.
50. Tremolada C, Colombo V, Ventura C. Adipose tissue and mesenchymal stem cells: state of the art and Lipogems® technology development. *Curr Stem Cell Rep* 2016; 2: 304-312.



51. Bianchi F, Maioli M, Leonardi E, Olivi E, Pasquinelli G, Valente S, Mendez AJ, Ricordi C, Raffaini M, Tremolada C, Ventura C. A new nonenzymatic method and device to obtain a fat tissue derivative highly enriched in pericyte-like elements by mild mechanical forces from human lipoaspirates. *Cell Transplant* 2013; 22(11): 2063-2077.
52. Tonnard P, Verpaele A, Peeters G, Hamdi M, Cornelissen M, Declercq H. Nanofat grafting: basic research and clinical applications. *Plast Reconstr Surg* 2013; 132(4): 1017-1026.
53. Rossi M, Alviano F, Ricci F, Vignoli F, Marchionni C, Valente S, Zannini C, Tazzari PL, Vignoli M, Bartoletti E, Bonsi L. In vitro multilineage potential and immunomodulatory properties of adipose derived stromal/stem cells obtained from nanofat lipoaspirates. *CellR4* 2016; 4(6): e2212.
54. Tremolada C, Palmieri G, Ricordi C. Adipocyte transplantation and stem cells: plastic surgery meets regenerative medicine. *Cell Transplant* 2010; 19(10): 1217-1223.
55. Coleman SR, Mazzola RF. *Fat injection: from filling to regeneration*. St. Louis, MO: Quality Medical Publishing, 2009.
56. Raffaini M, Tremolada C. Micro fractured and purified adipose tissue graft (Lipogems®) can improve the orthognathic surgery outcomes both aesthetically and in postoperative healing. *CellR4* 2014; 2(4): e1118.